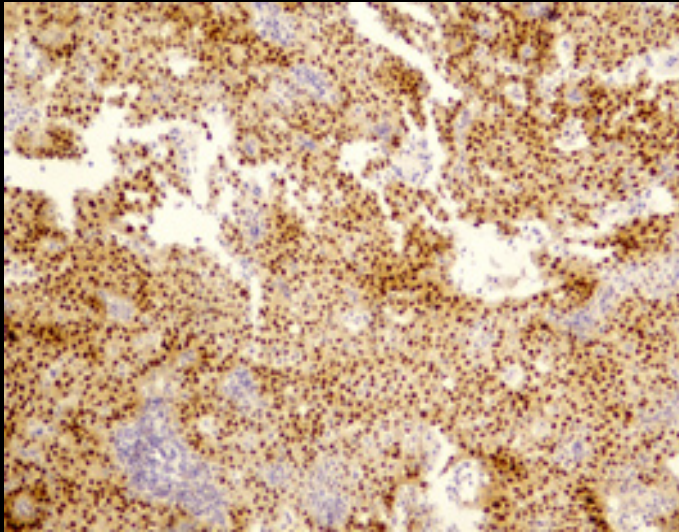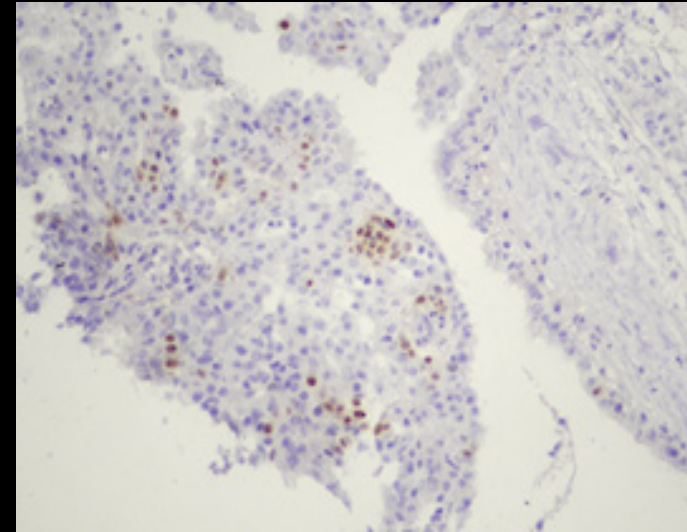


Non-morular cells showing immunoreactivity for PAX8 (X100)



Morular cells staining for p40 (x200)

REFERENCES:

1. Gonzalez-Gonzalez R, Bologna-Molina R, et al. Papillary thyroid carcinoma: differential diagnosis and prognostic values of its different variants: review of the literature. *ISRN Oncol.* 2011;915925.
2. Shubadha V. Kane, Izhar N. Bagwan. Cribriform-morular variant of papillary carcinoma: The sporadic counterpart of familial adenomatous polyposis-associated thyroid carcinoma. *Oral Oncology* 2006; 42: 167– 69
3. Kundu S, Sharan A, Sudhamani S, Singh S , Roplekar P, Swapnil V. Cribriform- morular variant of papillary thyroid carcinoma - a rare case report . *International journal of advances in case reports* 2016;3(10):426-28.
4. Liyanapathirana N, Seneviratne SA, Samarasekera D. A distinct variant of papillary thyroid carcinoma indicating familial adenomatous polyposis (FAP): a case report and brief review. *BMC Research Notes* 2015; 795-99.