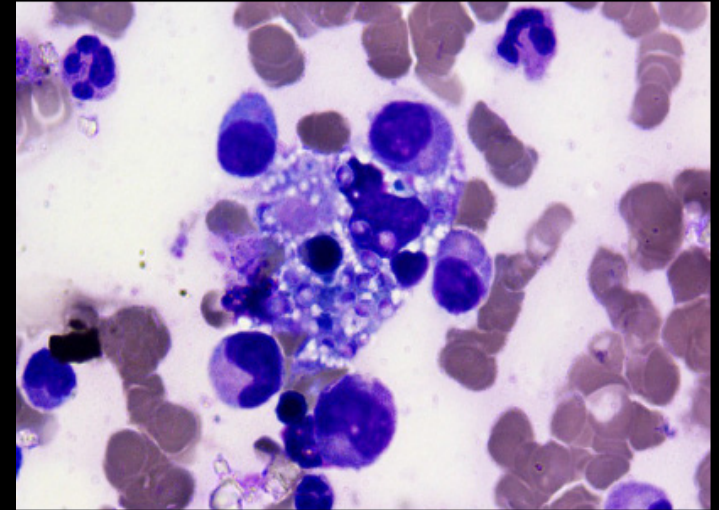


## BONE MARROW ASPIRATION FINDINGS:

- Bone marrow aspirate smears were cellular with adequate trilineage haematopoiesis
- It revealed an increase in histiocytes but there was no significant hemophagocytosis noted
- BM showed the presence of intracellular capsulated fungal structures morphologically suggestive of histoplasma. PAS stain was done on the aspirate smear and was positive in the fungal organisms (capsule)



- **Bone marrow biopsy findings:** Cellular bone marrow with prominence of histiocytes was noted with presence of intracellular fungal structures suggestive of histoplasma
- Hence a thorough morphological examination of bone marrow unveiled the diagnosis of an unsuspected fungal infection
- **Further clinical history was obtained:** There was no history of travel to an endemic region. There was no alleged high risk behaviour or a known immunocompromised state
- **Additional investigations:** Viral markers including HIV/HBS/HCV tests were ordered to confirm the immunocompromised state of the patient. Patient was found to be seropositive (HIV)
- CD4 count was 4cells/ul with Cd4:CD8 ratio of 0.05

