

CASE 054

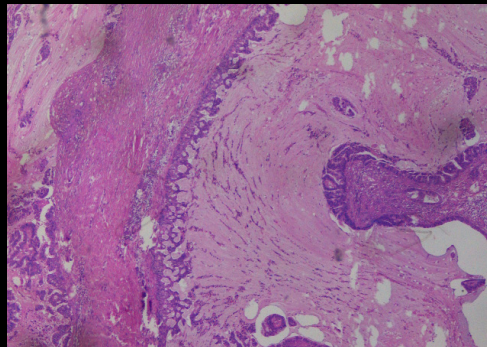
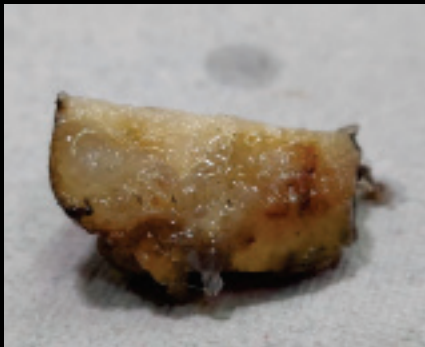AUTHORS: Ekta Jain MD, DNB, Abhishek Kumar, MD, Raajul Jain, MD.

ACKNOWLEDGMENTS: Gauraw Kumar.

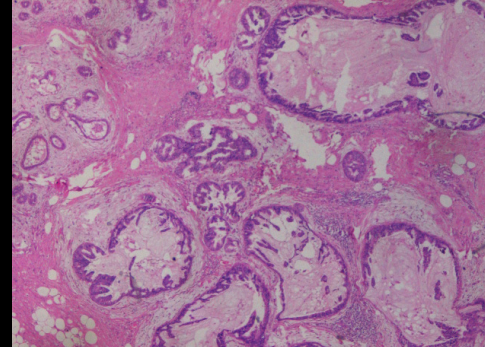
Primary Mucinous Cystadenocarcinoma of the Breast: A rare case with Review of literature

CLINICAL HISTORY:

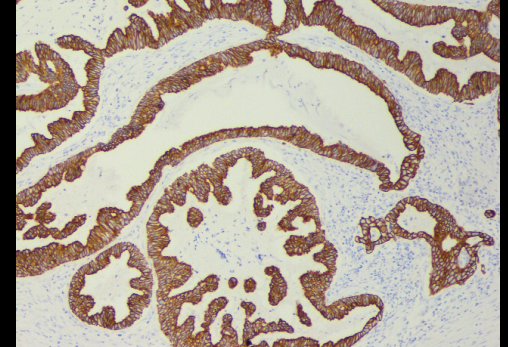
A 45-year-old female presented with pain and palpable mass in left breast since 1 month. All laboratory investigations of basic blood counts, including erythrocyte sedimentation rate, were within normal limits. Radiologic evaluations demonstrated a single slightly heterogenous hypoechoic mass having irregular micro-lobular margins in left breast on ultrasonography. A possibility of breast carcinoma was suggested and based on this, lumpectomy was planned and carried out.



H & E



H & E



CK7